

# Endoscopic Removal of Foreign Bodies- Judicious Approach is Must

Parveen Malhotra, Rahul Siwach, Devyani Verma, Bibin CF, Devyani Verma, Onkardeep Kaur

Department of Medical Gastroenterology & Anaesthesiology, PGIMS, Rohtak, Haryana, India

## \*Corresponding Author:

Parveen Malhotra, 128/19, Civil Hospital Road, Rohtak, Haryana, India

**Received Date:** 07 Mar 2026

**Accepted Date:** 27 Mar 2026

**Published Date:** 04 Apr 2026

Citation: Parveen Malhotra, Endoscopic Removal of Foreign Bodies- Judicious Approach is Must. IJGH; 2026; 1: 1-3

## 1. Abstract

**1.1. Introduction:** The children below three years of age are more predisposed for swallowing foreign body, luckily majority of them pass spontaneously without any complications. The endoscopic removal is required in approximately in 10 to 20 percent of patients. Further, in 1 % in which endoscopy fails or is not indicated require removal by surgery. As expected, mortality is low with foreign body ingestion but in rare cases death has been reported which usually occurs with sharp edged foreign bodies. The mentally retarded children are more predisposed and coins or toys are usual culprit. are the most common foreign bodies ingested by children. In certain cases, accidental ingestion of foreign body can occur in adults, especially in old age when reflexes become weak.

**1.2. Case Report:** A four -year-old male child, having no significant past history was playing with a pair of magnets and accidentally put them in his mouth which by chance slipped into stomach. He was so terrified by the idea that these magnets could only be removed surgically, hence hid it from his parents for few hours. Later on, due to his disturbed behaviour, on enquiring by parents, he revealed the truth. He was shown to local practitioner, who advised for x-ray abdomen which revealed a pair of magnets in his stomach. The practitioner suggested to wait for a day, so that it may come on its own. On second day, again x-ray abdomen was repeated which showed magnets in stomach but bit lower, thus prompting private practitioner for increasing waiting period for next two days, for self-removal of magnets with stools. The x-ray abdomen on fourth day revealed pair of magnets still in fundus of stomach, i.e. they again

have migrated from antrum to fundus of stomach. At this point of time, this boy was referred to our centre in fasting stage.

He was haemodynamically stable and was subjected to endoscopy by paediatric endoscope under sedation which revealed pair of magnets attached to each other and lying in fundus of stomach. The same were removed successfully with the help of basket. He was observed for few hours post-procedure and after satisfactorily starting on oral feeds, was discharged under haemodynamically stable condition. He and his family members were counselled regarding future precautionary measures regarding voluntary or accidental foreign body ingestion. We hereby report a case report of a 4-year-old child who ingested a pair of magnets accidentally while playing with them.

**1.3. Conclusion:** Endoscopic removal of ingested foreign bodies depends upon their nature. Hence, needles, pins, sharp edged, lithium batteries are removed on priority and other like coins are given time for passage with stools. In our case, the pair of magnets was stucked with each other due to magnetic nature, hence were not able to transverse through stomach for four days. Normally, foreign bodies will not take more than two days to come out with stools, hence waiting period of four days in our case by local practitioner was not justified.

**2. Keywords:** Magnet, Endoscopy, Foreign body, Basket, Sedation

## 3. Introduction

The children below three years of age are more predisposed for swallowing foreign body, luckily majority of them pass spontaneously without any complications [1-3]. The endoscopic removal is required in approximately in 10 to 20 percent of patients. Further, in 1 % in which endoscopy fails or is not indicated require removal by surgery [1,2,4] As expected, mortality is low with foreign body ingestion but in rare cases death has been reported which usually occurs with sharp edged foreign bodies [2,5,6]. A significant rise in the incidence of magnet ingestion by children has been recognized as a growing health issue worldwide [7], necessitating focused consideration [8-9]. Neodymium magnets are smaller than older generation magnets (5 mm) BUT ten to twenty times more powerful. Neodymium magnets are available both as magnets or as components of children's toys [10]. Neodymium magnets of 5 mm in size, can exert a force of up to a half kilogram between one another [11] and can cause ischemia, necrosis, and perforation of intervening gut walls [12-14]. However, the initial phase of magnet ingestion is asymptomatic followed by non-

specific symptoms such as pain, vomiting, or fever. Rarely do patients present with shock due to delayed reporting of magnets ingestion [15]. Furthermore, multiple magnetic foreign body ingestion may need surgical intervention if esophageal-gastric-duodenal endoscopy (OGDE) either fails to extract the magnetic beads or they are inaccessible [16]. Accumulating evidence from the literature emphasized that multiple magnet ingestion is more serious and increases the risk of hospitalization, surgical intervention, and complications [17-18].

#### 4. Case Report

A four-year-old male child, having no significant past history was playing with a pair of magnets and accidentally put them in his mouth which by chance slipped into stomach. He was so terrified by the idea that these magnets could only be removed surgically, hence hid it from his parents for few hours. Later on, due to his disturbed behaviour, on enquiring by parents, he revealed the truth. He was shown to local practitioner, who advised for x-ray abdomen which revealed a pair of magnets in his stomach. The practitioner suggested to wait for a day, so that it may come on its own. On second day, again x-ray abdomen was repeated which showed magnets in stomach but bit lower, thus prompting private practitioner for increasing waiting period for next two days, for self-removal of magnets with stools. The x-ray abdomen on fourth day revealed pair of magnets still in fundus of stomach, i.e. they again have migrated from antrum to fundus of stomach. At this point of time, this boy was referred to our centre in fasting stage. He was haemodynamically stable and was subjected to endoscopy by paediatric endoscope under sedation which revealed pair of magnets attached to each other and lying in fundus of stomach. The same were removed successfully with the help of basket. He was observed for few hours post-procedure and after satisfactorily starting on oral feeds, was discharged under haemodynamically stable condition. He and his family members were counselled regarding future precautionary measures regarding voluntary or accidental foreign body ingestion.

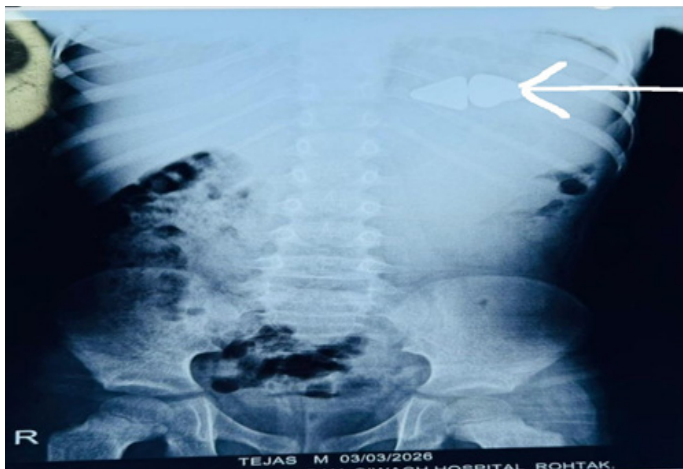

Figure 1- X-ray Abdomen Showing Pair of Magnets (Day 1)

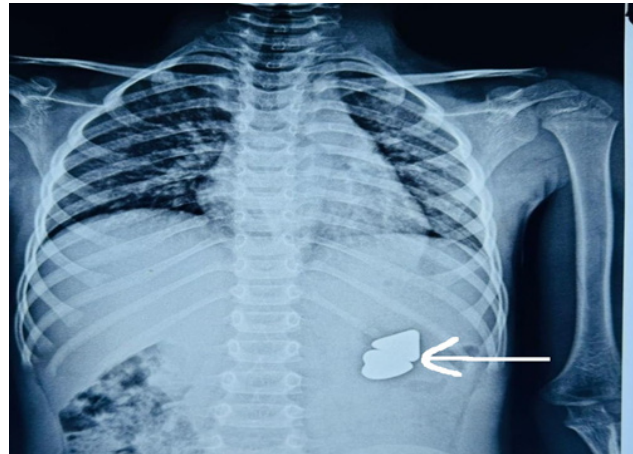


Figure 2- X-ray Abdomen Showing Pair of Magnets (Day 2)

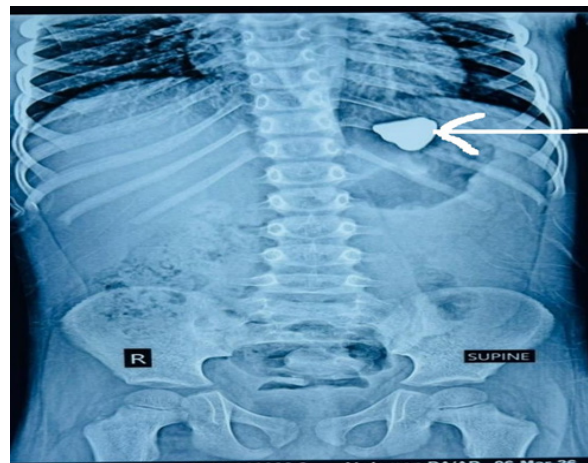


Figure 3- X-ray Abdomen Showing Pair of Magnets (Day 4)



Figure 4- Pair of Magnets after Endoscopic Removal

#### 5. Conclusion

Endoscopic removal of ingested foreign bodies depends upon

their nature. Hence, needles, pins, sharp edged, lithium batteries are removed on priority and other like coins are given time for passage with stools. In our case, the pair of magnets was stucked with each other due to magnetic nature, hence were not able to transverse through stomach for four days. Normally, foreign bodies will not take more than two days to come out with stools, hence waiting period of four days in our case by local practitioner was not justified. The timely and early removal could have easily removed the mental stress of the patient and family members which persisted for four days. Magnets have the potential to cause long-term health problems; hence parents and caregivers should ensure that toys or objects with magnets are kept out of reach. It is essential to immediately seek medical attention if a child has ingested magnets or if there is any suspicion of this having occurred.

#### Reference

1. Wyllie R. Foreign bodies in the gastrointestinal tract. *Curro pin Pediatr.* 2006; 18(5): 563-564
2. Uyemura MC. Foreign body ingestion in children. *Am FamPhysician.* 2005; 72(2): 287-291.
3. Banerjee R, Rao GV, Sriram PV, Reddy KS, Nageshwar Reddy D. Button battery ingestion. *Indian J Pediatr.* 2005; 72(2): 173-174.
4. Shivakumar AM, Naik AS, Prashanth KB, Yogesh BS, Hongal GF. Foreign body in upper digestive tract. *Indian J Pediatr.* 2004; 71(8):689-693.
5. Westmoreland D, Grigsby K, Brown L, Latessa P, Huber D. Replicating Project LINC in two midwestern states. Implications for policy development. *Nurs Health Care Perspect.* 1998; 19(4): 166-174.
6. Yardeni D, Yardeni H, Coran AG, Golladay ES. Severe oesophageal damage due to button battery ingestion: can it be prevented? *Pediatr Surg Int.* 2004; 20(7): 496-501
7. Seguier-Lipszyc E, Samuk I, Almog A, Silbermintz A & Kravarusic D. Multiple magnet ingestion in children: A problem on the rise. *J. Paediatr. Child Health.* 2022; 58(10): 1824–1828. <https://doi.org/10.1111/jpc.16117>.
8. Ding G. et al. Pediatric multiple high-powered magnetic buckyballs ingestion-experience from six tertiary medical centers. *Front. Public Health.* 2022; 10: 892756. <https://doi.org/10.3389/fpubh.2022.892756>.
9. Strickland M, Diamond IR & Rosenfield D. Case discussions and radiographic illustration of magnet-related injuries in children. *J. Emerg. Med.* 2020; 58(6): 902-909. <https://doi.org/10.1016/j.jemermed.2020.03.022>.
10. Cai DT, Shu Q, Zhang SH, Liu J & Gao ZG. Surgical treatment of multiple magnet ingestion in children: A single-center study. *World J. Clin. Cases.* 8(23); 5988-5998.
11. Mas E, Michaud L & Viala J. Let's stop lesions induced by magnet ingestion. *Arch. Pediatric.* 2019; 26(3): 131-32. <https://doi.org/10.1016/j.arcped.2019.01.002>.
12. Sola R, Rosenfeld EH, Yu YR, St Peter SD & Shah SR. Magnet foreign body ingestion: Rare occurrence but big consequences. *J. Pediatr. Surg.* 2018; 53(9): 1815-1819. <https://doi.org/10.1016/j.j.pedsurg.2017.08.013>.
13. Kodituwakku R, Palmer S & Paul SP. Management of foreign body ingestions in children: Button batteries and magnets. *Br. J. Nurs.* 2017; 26(8): 456-461. <https://doi.org/10.12968/bjon.2017.26.8.456>.
14. Nugud AA. et al. Pediatric magnet ingestion, diagnosis, management, and prevention: A European society for paediatric gastroenterology hepatology and nutrition (ESPGHAN) position paper. *J. Pediatr. Gastroenterol. Nutr.* 2023; 76(4): 523–532. <https://doi.org/10.1097/mpg.0000000000003702>.
15. Muhammad Afzal AAA, Abugrain HH, Alsaed MM, Alzahir BS & Sulis NA. Laparoscopic assisted extraction of multiple ingested magnets leading to entero-enteric fistulae: Case report of three patients. *J. Pediatr. Surg. Case Rep.* 2022; 84: 102357. <https://doi.org/10.1016/j.epsc.2022.102357>.
16. Rosenfield D, Strickland M & Hepburn CM. After the recall: Re-examining multiple magnet ingestion at a large pediatric hospital. *J. Pediatr.* 2017; 186: 78-81. <https://doi.org/10.1016/j.jpeds.2017.02.002>.
17. Hussain SZ. et al. Management of ingested magnets in children. *J. Pediatr. Gastroenterol. Nutr.* 2012; 55(3): 239-242. <https://doi.org/10.1097/MPG.0b013e3182687be0>.
18. Reeves PT, Nylund CM, Krishnamurthy J, Noel RA & Abbas MI. Trends of magnet ingestion in children, an ironic attraction. *J. Pediatr. Gastroenterol. Nutr.* 2018; 66(5): e116-e121. <https://doi.org/10.1097/mpg.0000000000001830>.